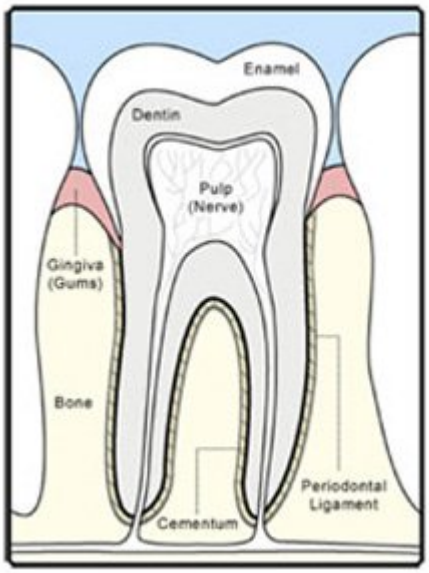

Bone: The "alveolar" bone contains the tooth roots. It forms the tooth socket and provides the tooth with support.

Cementum: A layer of tough, yellowish, bone-like tissue that covers the root of the tooth. It helps hold the tooth in the socket. The cementum attaches the tooth to the bone by a network of fibers known as the periodontal ligament.

Dentin: The hard but porous tissue located under both the enamel and cementum of the tooth. Dentin is similar to, but harder than, bone.

Enamel: The tough, shiny, "white" outer surface of the tooth that is visible. Enamel is actually translucent and reflects the color of the dentin which is under it. Enamel is the hardest substance in the body.

Gingiva (gums): The firm, pink flesh that covers the bones and surrounds the teeth.

Periodontal ligament: The fibrous tissue between the tooth and the tooth socket. It holds the tooth in place.

Pulp (nerve): The soft center of the tooth. The pulp contains blood vessels and nerves; it nourishes the dentin.

Primary Teeth

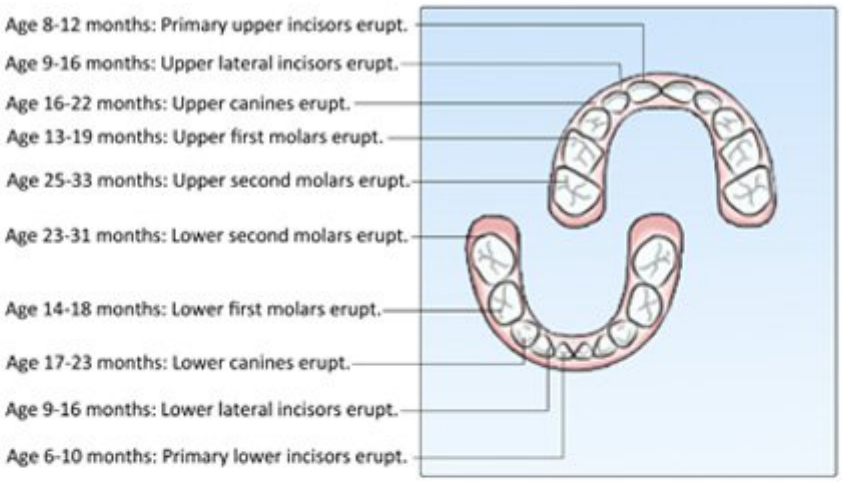
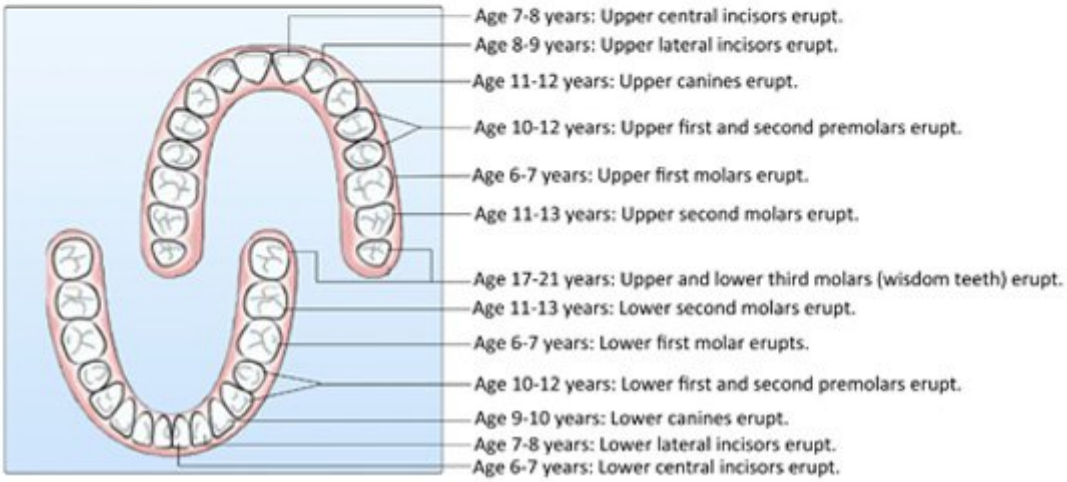
Adult Teeth